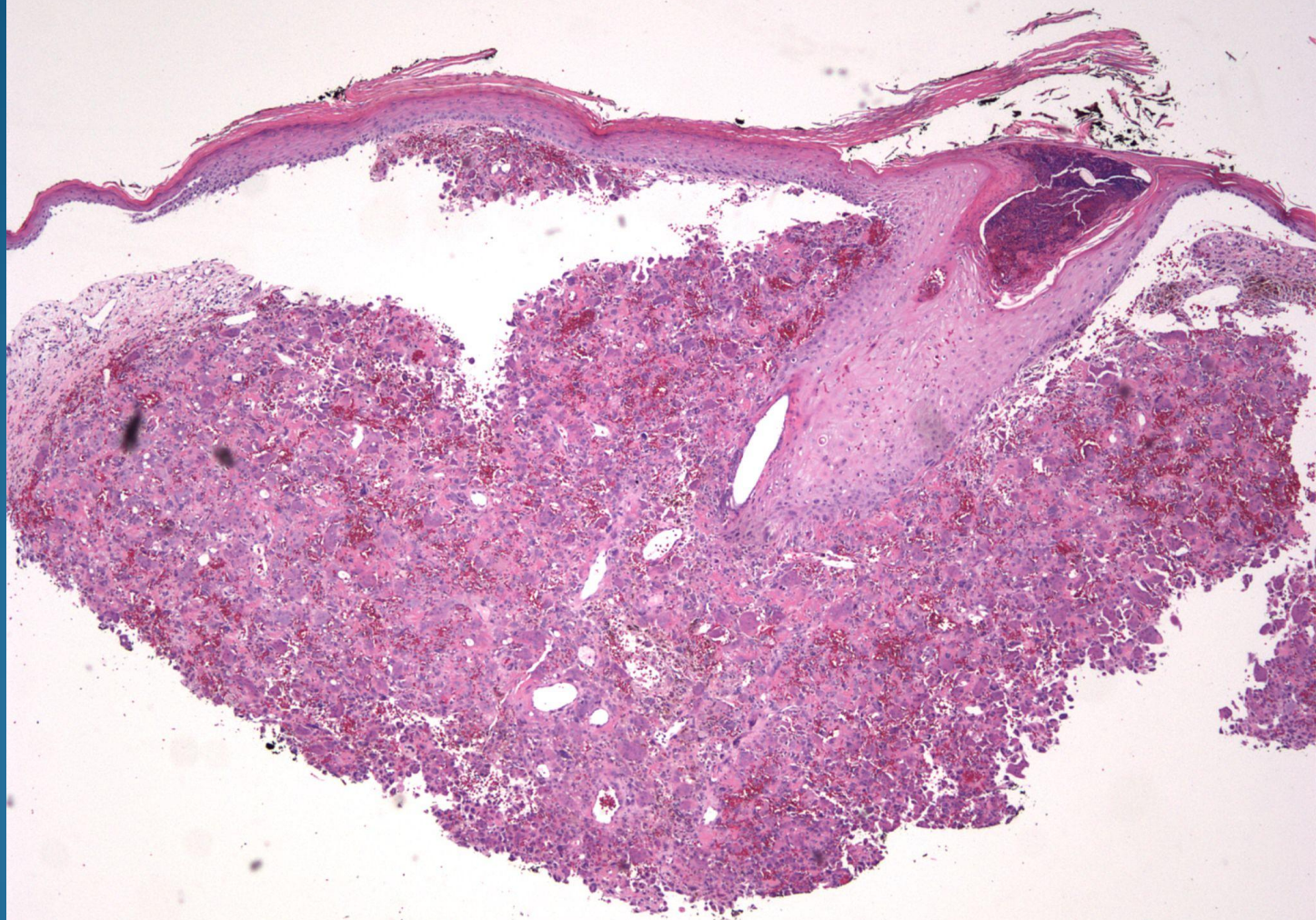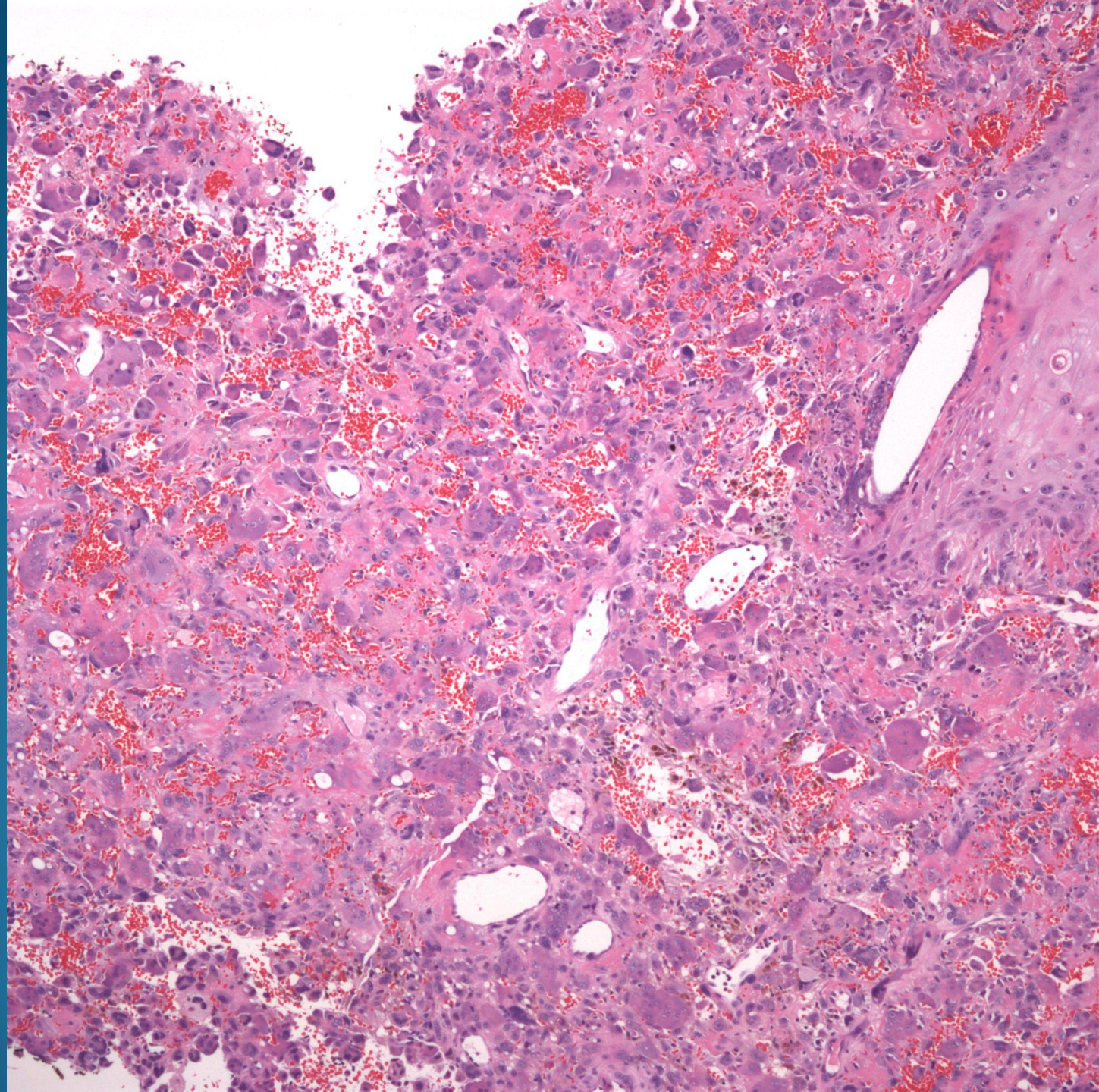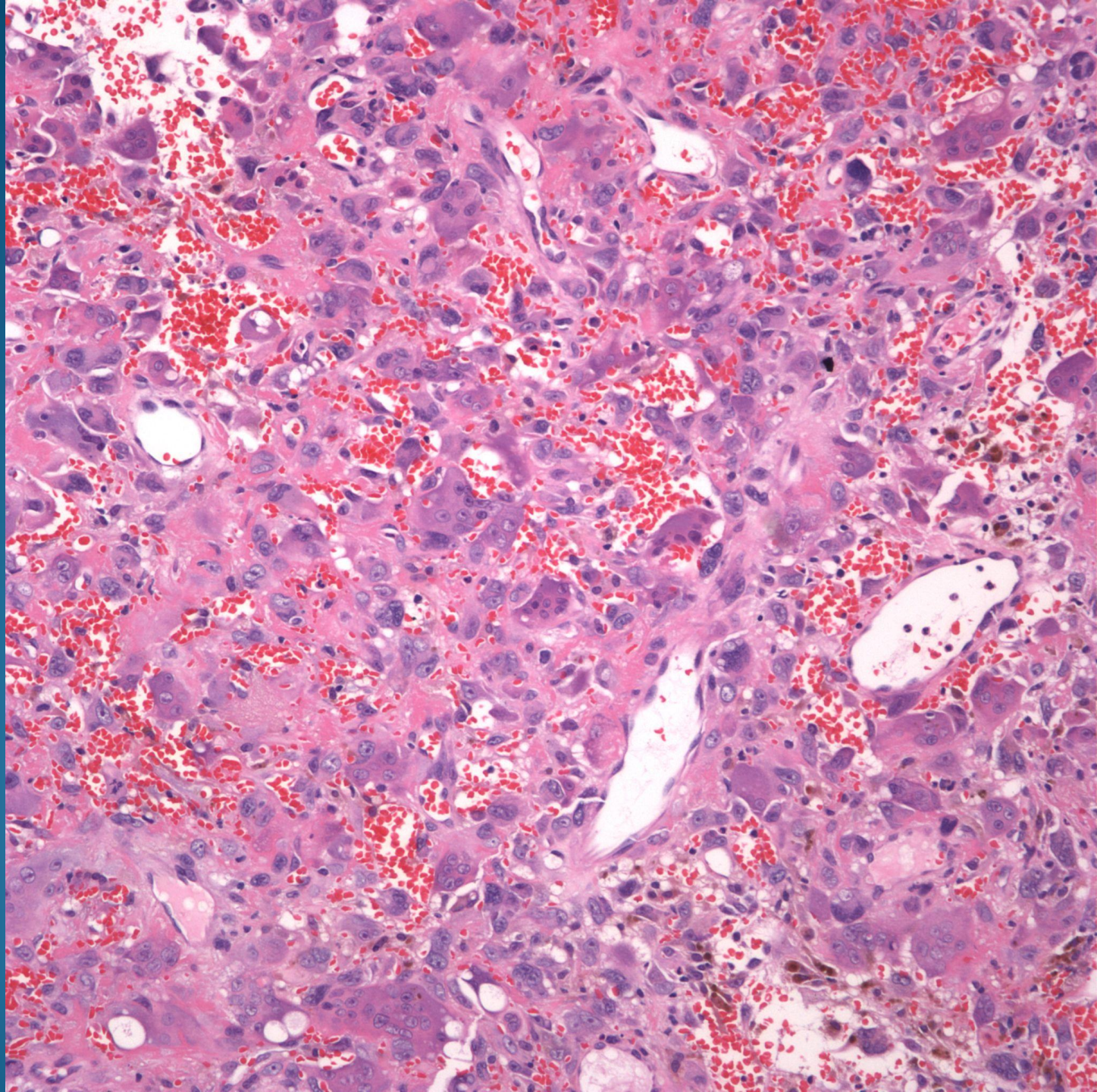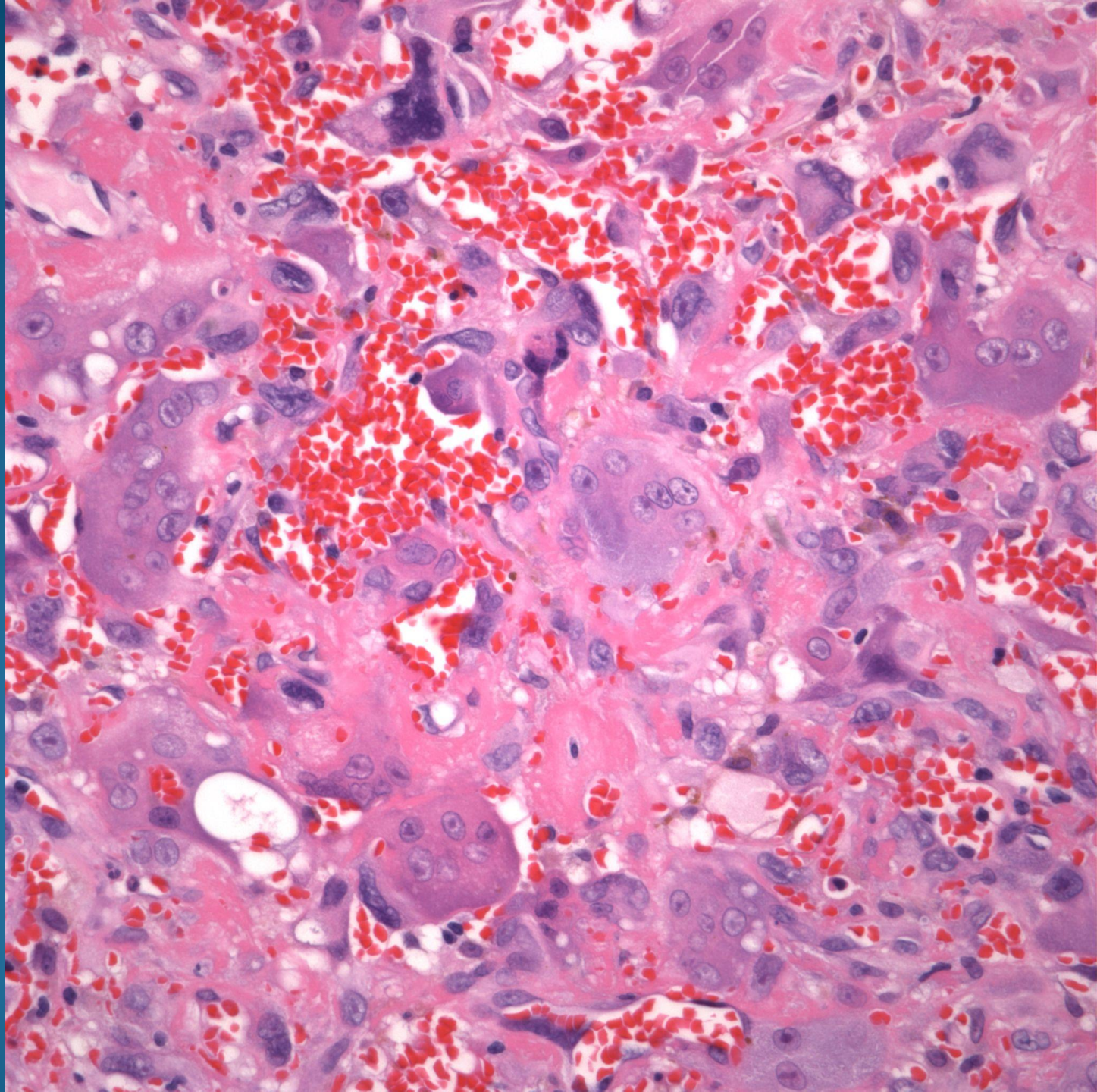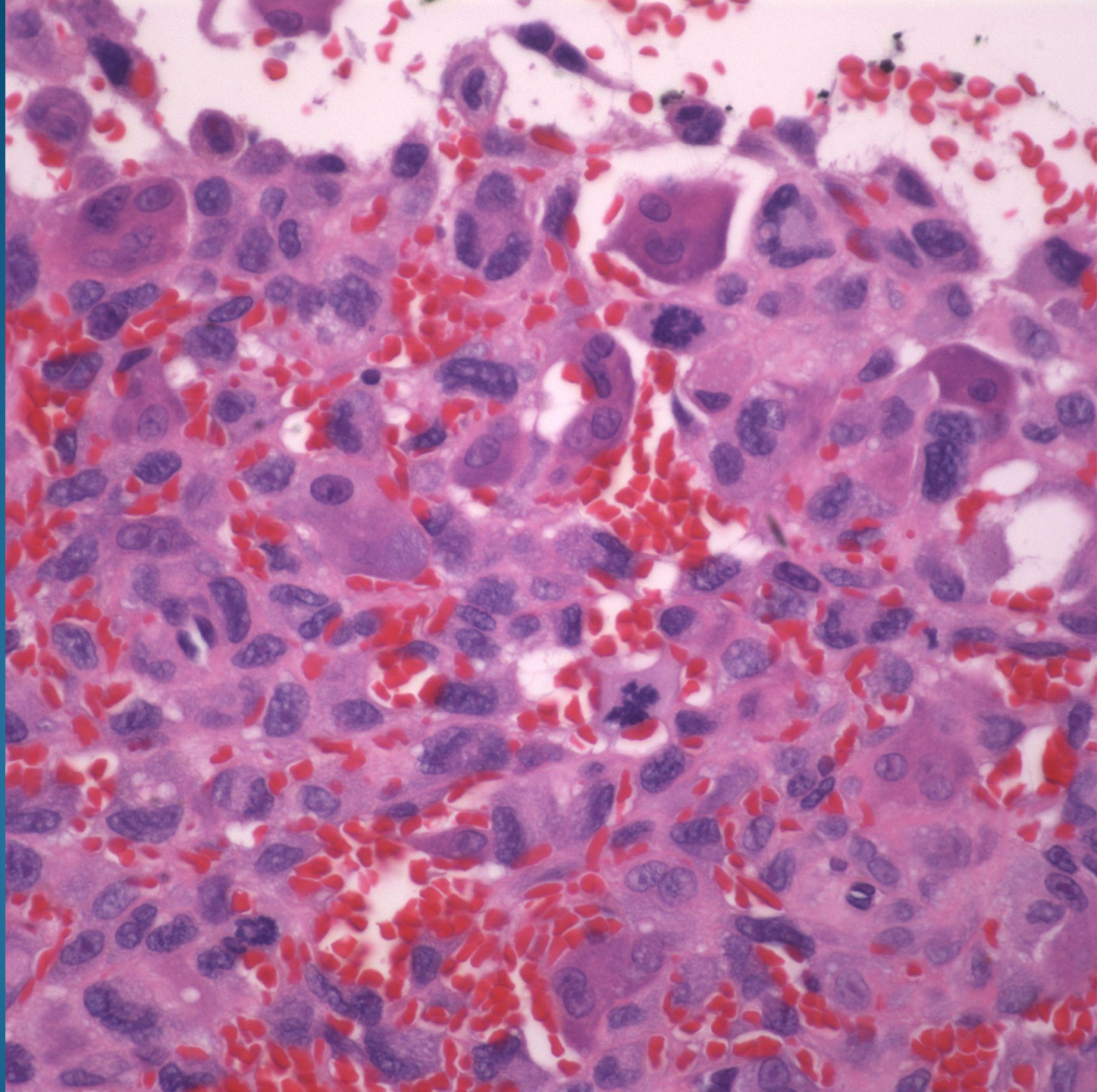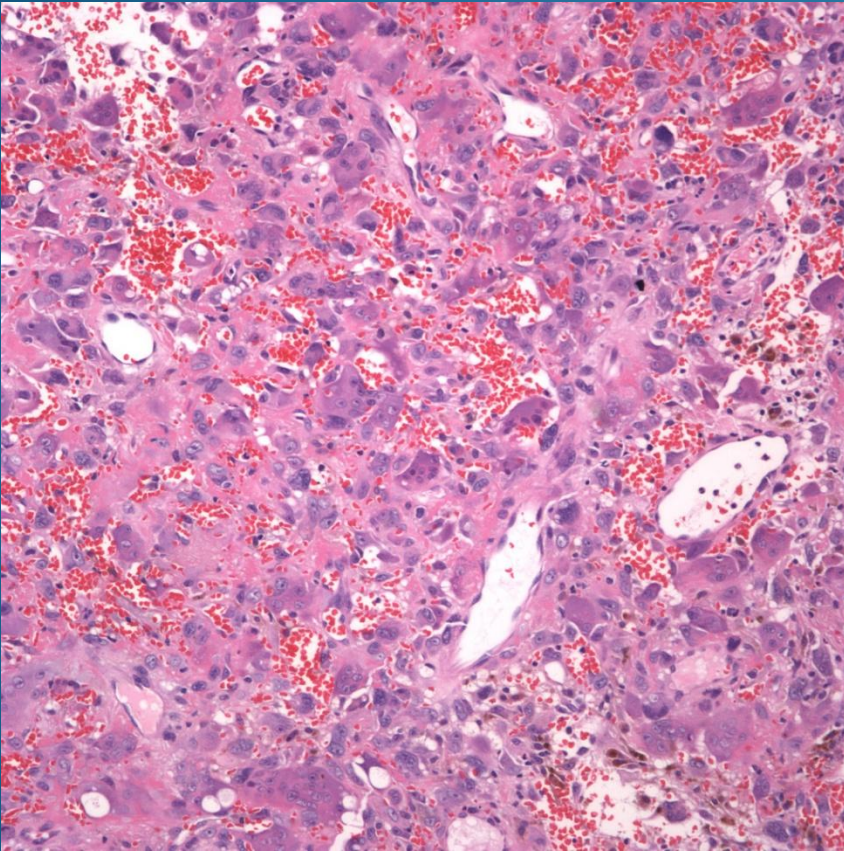


Malignant Giant Cell Tumor of the Skin

Pearls



- Numerous cytologically malignant giant cells surrounded by similar appearing mononuclear cells
- DX of exclusion
- IHC to rule out carcinoma, AFX, angiosarcoma
- Rule out underlying tumor extending into skin